



**CASE REPORT**

# Actinomycosis in the oral cavity after squamous cell carcinoma: colonization or recurrence?

Thiago Câmara de Souza Barbalho<sup>1\*</sup>, Emerson Kennedy Ribeiro de Andrade Filho<sup>1</sup>, Sheila Ramos de Miranda Henriques<sup>1,2</sup>, Marina Mayara Batista do Rêgo<sup>2</sup>, Gabriel Melo Caldas Nogueira<sup>1</sup>, Eduardo Otto Gomes<sup>1</sup>

## Abstract

Actinomycosis is a chronic, rare bacterial infection caused by *Actinomyces israelii*. It primarily affects the oropharynx, gastrointestinal tract, and genitourinary system, with the oropharynx being the most common site. Risk factors for the development of this infection include breaches in the oral cavity, chronic infections in the head and neck region, and immunosuppression. Diagnosing actinomycosis can be challenging because of its clinical presentation, which often mimics other benign and malignant disorders. Here, we report the case of a 57-year-old woman who underwent a COMMANDO (combined mandibulectomy and neck dissection operation) followed by combined radiotherapy and chemotherapy. This treatment was initiated after identifying a lesion on the tongue extending to the lower gums suggestive of squamous cell carcinoma (pT4aN0M0 staging) in an anatomopathological study. Five months later, the patient developed pain and paresthesia in the region of the surgical wound and presented with a granulomatous and vegetating lesion in the lower right alveolar ridge. Pathological analysis identified this new lesion as compatible with *Actinomyces* sp. However, a subsequent analysis, conducted after an attempt to treat the infection, revealed that the lesion was a recurrence of the carcinoma.

**Keywords:** cervicofacial actinomycosis; actinomyces infection; oral leukoplakia.

**How to cite:** Barbalho TCS, Andrade Filho EKR, Henriques SRM, Rêgo MMB, Nogueira GMC, Gomes EO. Actinomycosis in the oral cavity after squamous cell carcinoma: colonization or recurrence? Arch Head Neck Surg. 2023;52:e20230027. <https://doi.org/10.4322/ahns.2023.0027>

## Introduction

Actinomycosis is a chronic, rare bacterial infection primarily caused by *Actinomyces israelii*. Although this colonial bacterium is part of the commensal flora of the oropharynx, gastrointestinal tract, and genitourinary system, conversion from colonization to an infectious process is rare because of the low pathogenicity of this agent<sup>1</sup>.

The disease is more prevalent in areas with low socio-demographic development and fragile health as a result of poor dental hygiene, lack of basic health knowledge, and restricted access to healthcare in these areas<sup>2</sup>.

<sup>1</sup>Universidade Federal do Rio Grande do Norte (UFRN), Natal, RN, Brasil

<sup>2</sup>Liga Norte Riograndense Contra o Câncer (LNRCC), Serviço de Cirurgia de Cabeça e Pescoço, Natal, RN, Brasil

**Financial support:** None.  
**Conflicts of interest:** No conflicts of interest declared concerning the publication of this article.  
**Submitted:** July 05, 2023.  
**Accepted:** November 27, 2023.

The study was carried out at Liga Norte Riograndense Contra o Câncer, Natal, RN, Brasil.



Copyright Barbalho et al. This is an Open Access article distributed under the terms of the Creative Commons Attribution License, which permits unrestricted use, distribution, and reproduction in any medium, provided the original work is properly cited.

Here, we report the case of a 57-year-old woman who underwent COMMANDO (combined mandibulectomy and neck dissection operation) followed by combined adjuvant radiotherapy and chemotherapy. This treatment was initiated after identifying a lesion on the tongue extending to the lower gums suggestive of squamous cell carcinoma. Five months later, the patient presented with a granulomatous and vegetating lesion in the lower right alveolar ridge. Histopathological analysis of the excisional biopsy specimen identified this new lesion as compatible with *Actinomyces* sp. infection.

## Case report

A 57-year-old female patient was referred to the Head and Neck Surgery service by the Dentistry service to treat a lesion on the tongue and oral mucosa with insidious growth, eventually reaching the anterior part of the lower gum. Additionally, there were no palpable lymphadenopathies. An incisional biopsy was performed, which suggested a finding of squamous cell carcinoma. After this, a computed tomography (CT) scan of the face and neck revealed a 2.2 x 1.2 cm lesion in the lower gum, causing erosions in the mandibular body, associated with homogeneous and slightly prominent lymph nodes, nonspecific, with no signs of malignancy, measuring up to 0.9 cm in the Ia and Ib bilateral levels, thus characterizing a cT4aN0M0 stage tumor.

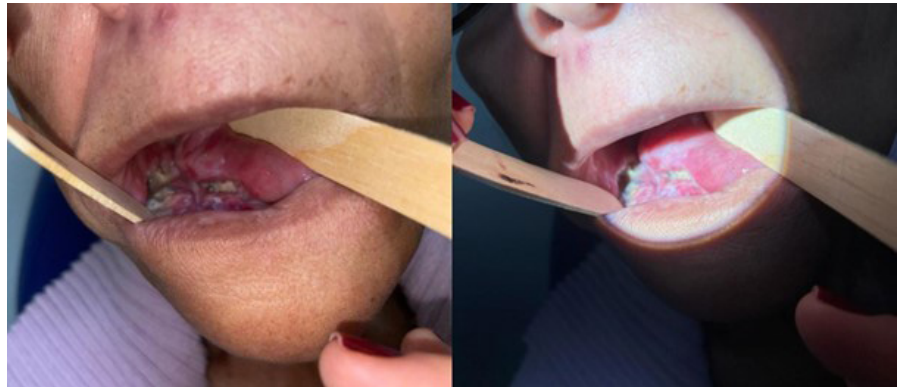Consequently, the patient underwent COMMANDO, with fixation of a plate in the remaining mandible and a platysma myocutaneous flap, combined with bilateral supraomohyoid neck dissection. The pathological report confirmed an invasive, conventional, keratinizing, well-differentiated squamous cell carcinoma measuring 2.7 x 1.1 cm, with invasion of the mandibular cortex and compromised margins in the first resection, but with clear margins in the extended resection, and no neoplastic lymph nodes (staging pT4aN0Mx).

Subsequently, the patient was referred to the Clinical Oncology service, where adjuvant treatment with radiotherapy was chosen. Moreover, because of uncertainty about the clear margins, the Clinical Oncology service decided to perform three cycles of adjuvant chemotherapy with cisplatin, according to National Comprehensive Cancer Network (NCCN) guidelines.

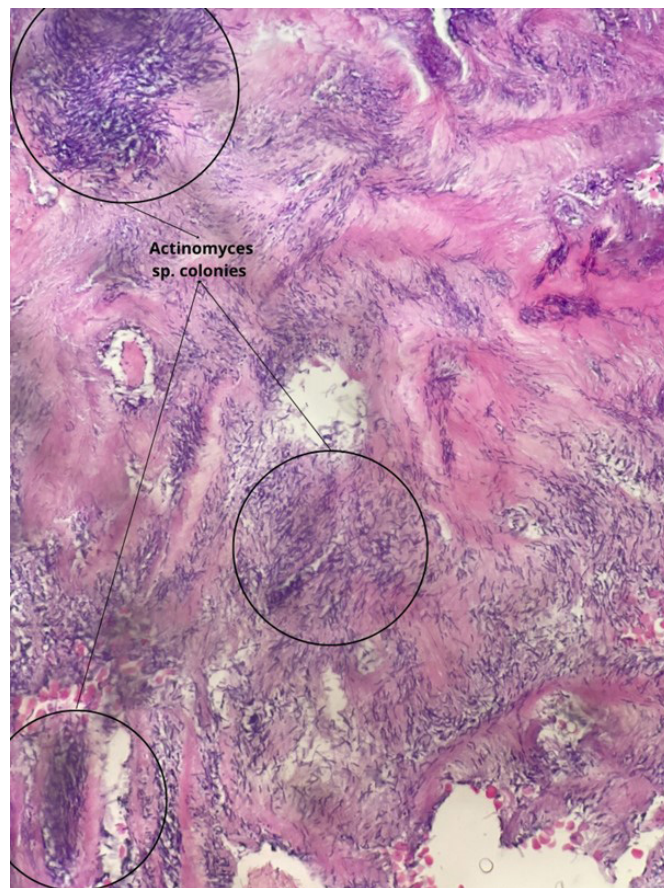
Five months after the surgical procedure, the patient reported pain and paresthesia in the area of the surgical wound and presented with a granulomatous and vegetating lesion in the lower right alveolar ridge (Figure 1). An excisional biopsy was opted for treatment and diagnostic clarification. After the biopsy, the patient continued to experience symptoms.

Histopathological analysis of the biopsy specimen revealed bacterial colonies suggestive of *Actinomyces* sp. (Figure 2). Therefore, antibiotic therapy was initiated with oral amoxicillin 2 g every 12 hours for 6 weeks, in addition to surgical debridement of the lesion.

Despite completing the antibiotic therapy, the patient continued to experience pain and paresthesia at the site of the surgical wound, and part of the lesion on the lower right alveolar ridge remained. Thus, a new excisional biopsy was performed, and the histopathological study revealed a recurrence of the initial neoplastic lesion, necessitating a new surgical approach.



**Figure 1.** Photograph of the oral examination showing a granulomatous and vegetating lesion in the lower right alveolar ridge region.



**Figure 2.** Histopathological examination showing findings suggestive of *Actinomyces* sp. (*Actinomyces* colonies circled amidst the oral cavity tissue).

## Discussion

Actinomyces is an infectious process that can mimic benign and malignant diseases<sup>3</sup>. The cervicofacial, thoracic, abdominal, pelvic, cerebral, laryngeal, and urinary regions are the most affected sites<sup>2</sup>.

Risk factors associated with its infectious development in the oropharyngeal region include aggressions to the oral cavity (such as surgical procedures, trauma, radiotherapy, and cavities), chronic infections in the head and neck region, and immunosuppression<sup>1</sup>. Additionally, the literature has reported actinomycosis as a complication following radiotherapy<sup>4</sup>.

Cervicofacial actinomycosis presents as a palpable slow-growing mass, of chronic nature, and vegetative appearance. There may be swelling and erythema of the soft tissues, with the formation of fistulas and multiple abscesses<sup>1</sup>. However, because of the large number of factors associated with this infection<sup>1</sup>, its diagnosis is often delayed<sup>2</sup>. Treatment includes surgical debridement or parenteral antibiotic therapy, but some oral antibiotic therapy regimens for 1-4 weeks have proven curative<sup>2</sup>.

Ideally, diagnosis is performed through culture, but it is negative in approximately half of the cases. An alternative to culture diagnosis is the identification of typical colonies in histopathological analysis<sup>5</sup>.

The treatment can vary depending on whether the etiology is mono- or poly-bacterial, as well as the extent of the infection. For severe and extensive actinomycosis cases, surgical debridement and intravenous antibiotic therapy with Penicillin G or Ceftriaxone for 4 to 6 weeks may be needed, followed by oral Penicillin V or Amoxicillin for 6 to 12 months. For mild cases, only parenteral treatment with oral Penicillin V or Amoxicillin for 2 to 6 months is recommended, with duration individualized based on the initial disease load, site of infection, success of surgical debridement, and clinical and radiological response to treatment<sup>2</sup>.

In this case report, *Actinomyces* sp. was identified in the histopathological study of a patient with a lesion that appeared after treatment for squamous cell carcinoma in the oral cavity. In cases like this, caution is necessary because the presence of this bacterium can be due to colonization, while the lesion may be a recurrence of the neoplasm. This study reinforces the need for rigorous follow-up in patients being treated for *Actinomyces* sp. infections in the presence of lesions suspicious for malignancy, aiming at a rapid response in case of therapeutic failure, combined with caution regarding the broad spectrum of differential diagnoses and the possibility of tumor recurrence.

## Ethical aspects

The patient agreed to the publication of this study by signing an Informed Consent Form. This study was approved by the Research Ethics Committee of the Liga Norte Riograndense Contra o Câncer.

## References

1. Karanfilian KM, Valentin MN, Kapila R, Bhate C, Fatahzadeh M, Micali G, Schwartz RA. Cervicofacial actinomycosis. *Int J Dermatol*. 2020;59(10):1185-90. <http://dx.doi.org/10.1111/ijd.14833>. PMID:32162331.
2. Boyanova L, Kolarov R, Mateva L, Markovska R, Mitov I. Actinomycosis: a frequently forgotten disease. *Future Microbiol*. 2015;10(4):613-28. <http://dx.doi.org/10.2217/fmb.14.130>. PMID:25865197.

**\*Correspondence**

Thiago Câmara de Souza Barbalho  
Universidade Federal do Rio Grande do Norte (UFRN), Centro de Ciências da Saúde  
Rua General Gustavo Cordeiro de Faria, 601, Ribeira  
CEP 59012-570, Natal (RN), Brasil  
Tel.: +55 (84) 99933-9811  
E-mail: thiagobarbalho2001@gmail.com

**Authors information**

TCSB, EKRAF, GMCN, EOG - Medical students, Centro de Ciências da Saúde, Universidade Federal do Rio Grande do Norte,

SRMH - Professor, Centro de Biociências, Universidade Federal do Rio Grande do Norte; Head and neck surgeon, Liga Norte Riograndense Contra o Câncer, MMBR - Head and neck surgeon, Liga Norte Riograndense Contra o Câncer.

3. Atespare A, Keskin G, Erçin C, Keskin S, Camcioglu A. Actinomycosis of the tongue: a diagnostic dilemma. *J Laryngol Otol.* 2006;120(8):681-3. <http://dx.doi.org/10.1017/S0022215106001757>. PMID:16716241.
4. Martos Plasencia C, Olivencia Palomar P, Patón Arenas R, Verdejo Gil C, Salmoral Luque R, Peña Gómez M, De la Santa Belda E, López Viedma B, Olmedo Camacho J. Actinomyces infection as a complication of a post-radiotherapy rectal ulcer. *Rev Esp Enferm Dig.* 2016;108(9):580-1. PMID:27615019.
5. Abbaszadeh H, Sheibani MSA. Actinomycotic osteomyelitis of mandible. *J Craniofac Surg.* 2016;27(5):e452-4. <http://dx.doi.org/10.1097/SCS.0000000000002793>. PMID:27391512.