




**ORIGINAL ARTICLE**

# Anatomy of the anterior jugular veins: anatomical study of 30 cadavers

Flávio Carneiro Hojaj<sup>1</sup> , Lesley Mirian de Paula Santos<sup>2</sup> ,  
Raquel Ajub Moyses<sup>1</sup> , Bruna Dos Santos Souza<sup>2</sup> , Flávia Emi Akamatsu<sup>1</sup> ,  
Bruna Brasil Carneiro Costa<sup>3</sup> , Lucas Albuquerque Chinelatto<sup>1\*</sup> ,  
Alfredo Luiz Jacomo<sup>1</sup> 

## Abstract

**Introduction:** Human anatomy is essential for both clinical and surgical practice. Although the anterior jugular veins (AJVs) are of great importance in many surgeries, there are few studies addressing the anatomic variations of these vessels. This study highlights the venous drainage of the head and neck and the importance of anatomical variations in the AJVs. **Objective:** To observe and describe the anatomy of the jugular veins and evaluate whether there are patterns influenced by anthropometric factors or comorbidities. **Methods:** Neck dissections were performed on 30 cadavers. The anatomical characteristics of the AJVs were described considering diameter, midline distance, anastomosis, and presence of the jugular venous arch. **Results:** Cadavers of 14 women and 16 men were dissected. Ninety percent (90%) of the jugular veins had a rectilinear path and 37% presented anastomosis: H-shaped (63.7%), N-shaped (27.3%), and Y-shaped (9%). In relation to the number of veins, 20% of the cadavers had only one AJV, 63.3% had two, 10% had three, and 6.7% presented a total of four. Mean distance between jugular veins was 12 mm, and most veins (60%) had a diameter <5 mm. There was no statistically significant correlation between anatomical variations and anthropometric factors. **Conclusion:** AJVs were always present in the dissected cadavers, and the configuration most commonly found was two veins, each <5 mm in diameter. They were less than 10 mm away from the cervical midline and, when they presented anastomosis, it was H-shaped in most cases.

**Keywords:** anatomy; jugular veins; neck dissection.

**How to cite:** Hojaj FC, Santos LMP, Moyses RA, Souza BS, Akamatsu FE, Carneiro BBC, Chinelatto LA, Jacomo AL. Anatomy of the anterior jugular veins: anatomical study of 30 cadavers. Arch Head Neck Surg. 2022;51:e20220005. <https://doi.org/10.4322/ahns.2022.0005>

## Introduction

Blood drainage from the head and neck is performed by the jugular venous system. This system has deep and superficial veins: the deep ones are the internal jugular veins, and the superficial ones are the anterior jugular veins (AJVs) and the external jugular veins<sup>1</sup>.

<sup>1</sup>Universidade de São Paulo (USP), Faculdade de Medicina (FM), São Paulo, SP, Brasil

<sup>2</sup>Universidade de São Paulo (USP), Escola de Enfermagem (EE), São Paulo, SP, Brasil

<sup>3</sup>Hospital Governador Celso Ramos, Florianópolis, SC, Brasil

**Financial support:** None.

**Conflicts of interest:** No conflicts of interest declared concerning the publication of this article.

**Submitted:** September 08, 2021.

**Accepted:** October 01, 2021.

This study was carried out at Faculdade de Medicina (FM), Universidade de São Paulo (USP), São Paulo, SP, Brasil.



Copyright Hojaj et al. This is an Open Access article distributed under the terms of the Creative Commons Attribution License, which permits unrestricted use, distribution, and reproduction in any medium, provided the original work is properly cited.

The internal jugular veins are a pair of veins that drain blood from the brain, the neck, and the superficial areas of the face<sup>2</sup>. They emerge from the skull through the jugular foramen, follow the neck vertically, and join the subclavian vein to form the brachiocephalic vein. The external jugular veins drain blood mainly from the scalp and face<sup>3</sup>. Usually, they are formed by the confluence of the retromandibular vein and the posterior tributaries of the posterior auricular vein, and run alongside the sternocleidomastoid muscle, ending in the subclavian vein.

The AJV has a smaller diameter compared with that of the other jugular veins. It usually emerges from the supra-hyoid region through the confluence of the superficial veins. It drains the submental region and the anterior portion of the neck. It runs between the imaginary midline of the neck and the anterior border of the sternocleidomastoid muscle<sup>2</sup>. Near the superior thoracic aperture, the AJVs run laterally, under the sternocleidomastoid muscle, and end in the external jugular vein. Immediately above the sternum, the AJVs on both sides communicate with each other through an arch - the jugular venous arch.

Knowledge about the anatomy of these vessels is important in surgical practice and in cervical surgeries such as tracheostomy, thyroidectomy, and cricothyroidotomy<sup>4</sup>. These procedures occur within the territory where the AJVs are located, and thus may cause vascular lesions or postoperative complications such as hemorrhage.

These veins can present important anatomical variations: they are closer to each other and to the cervical midline and further from the anterior wall of the sternocleidomastoid muscle, vein anastomosis (jugular venous arch) occurs above its usual presentation, presence of only one AJV, and presence of a third vein<sup>5-7</sup>. Unawareness of these variations may lead to significant lesions.

Important information about the anatomy of the AJVs can be found in the literature; however, there are no studies addressing their anatomy, syntopy, and anatomical variation frequency.

This study aims mainly to describe the variations and syntopy of the AJVs. As secondary objective, an investigative analysis was performed to search for possible associations of anthropometric factors with our findings.

## Methods

Aiming to study the position of the AJVs, the cadavers of 30 adults (14 women and 16 men) aged >18 years were dissected within 24 h of their death. Cadavers with diseases, treatments, and surgical procedures in the cervical region were excluded from the study.

All dissections were performed in the Inpatient Death Verification Service (IDVS) of the University Hospital of the aforementioned Institution by the same author (FCH), who is a head and neck surgeon. The project in which this investigation was included was approved by the Research Ethics Committee of the Institution under number 162/13.

The dissection technique used no magnification. It consisted of a biacromial incision followed by an infraclavicular flap, with anterior cervical exposure

and exposure of the superficial lamina of the cervical fascia. The AJVs were then macroscopically evaluated for the following characteristics: number, diameter, position, path, distance from cervical midline, presence and location of anastomosis, presence and location of jugular venous arch (Appendix 1). Measurements were made using an analogical caliper.

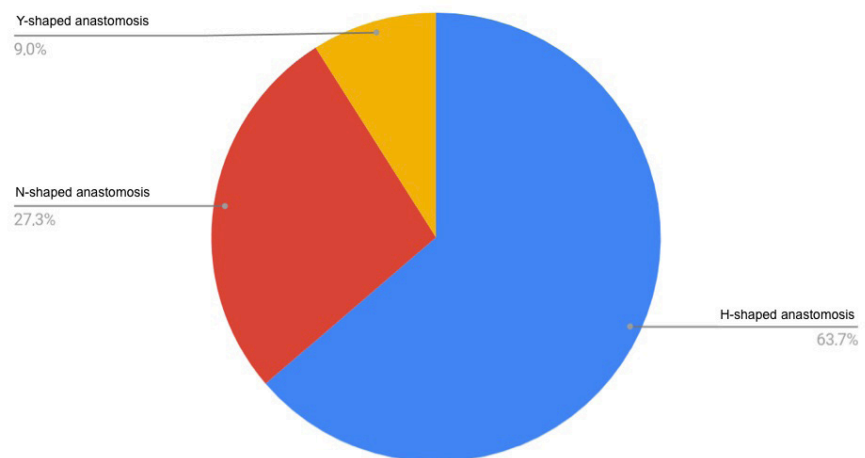
Anthropometric data were collected from the medical records of the IDVS. Only the following parameters were available: sex, height, and weight. Data analysis was performed using the Wilcoxon Signed-Rank Test for the nonparametric continuous variables and the Fisher's Exact Test was applied to evaluate the correlations between discrete variables. All data were processed using the JMP-SAS11 software.

## Results

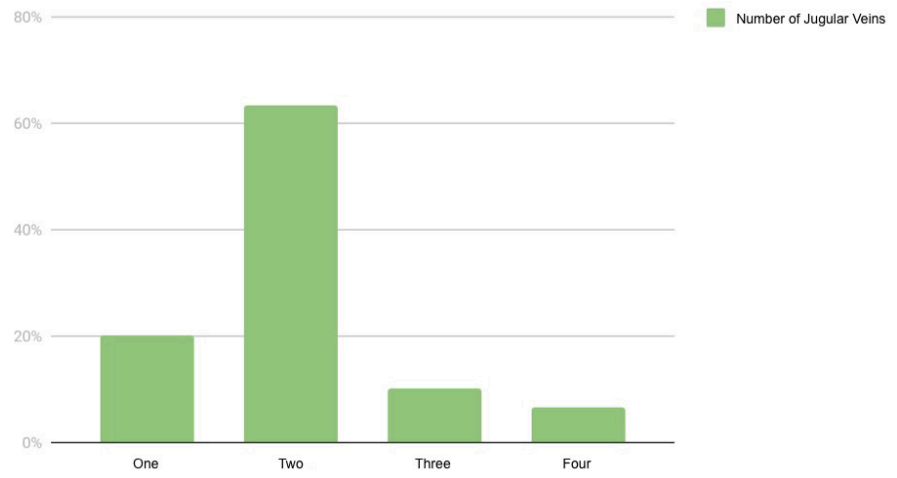
The study sample consisted of 14 women and 16 men. Age range was 36-92 years for men and 55-87 years for women. Median age was 71 years. Color distribution was 76% white and 24% black or brown.

Regarding the anatomical characteristics of the AJVs, 90% of the cadavers showed a rectilinear path, and 63% of them presented no anastomosis. When present (37%), anastomosis was located mainly in the medial region and consisted of three main types: H-shaped, N-shaped, and Y-shaped (Figure 1). Most cadavers had two AJVs (Figure 2). Distance from the cervical midline varied little: 56.7% of the AJVs were less than 10 mm away and 43.3% of them were more than 1 cm away. The mean distance between the AJVs was 1.2 cm, excluding the cases in which there was only one vein. Regarding diameter, 60% of the sample had veins with diameter <5 mm and 40% with diameter  $\geq$ 5 mm.

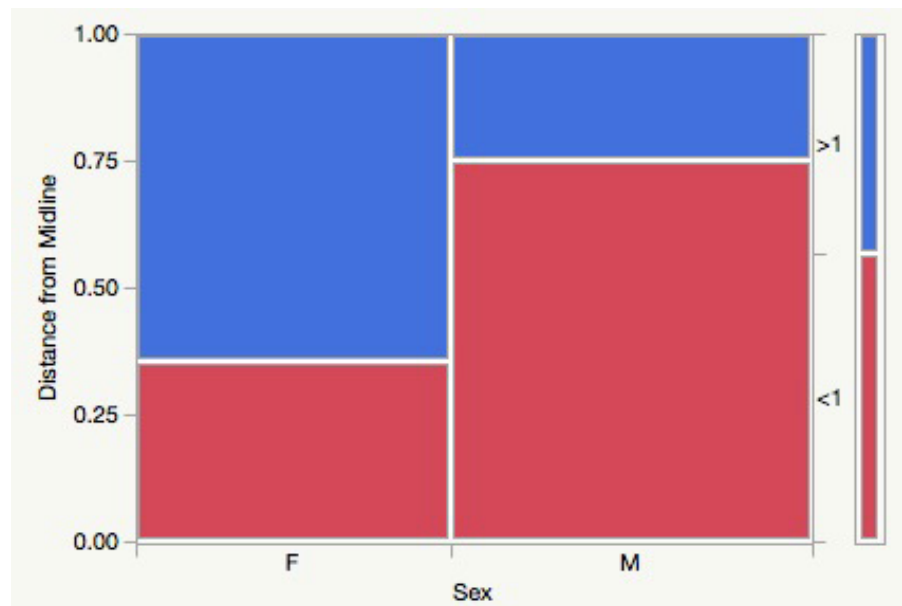
Our investigative analysis showed no statistically significant correlations between anatomical parameters and anthropometric factors. Only sex and distance between veins and to cervical midline (Figure 3) suggested correlation ( $\chi^2=0.03$ ), but did not prove to be statistically significant (Fisher,  $p=0.06$ ).



**Figure 1.** Distribution according to Type of Anastomosis.



**Figure 2.** Distribution according to the Number of Anterior Jugular Veins.



**Figure 3.** Correlation between Sex and Distance from the Anterior Jugular Veins to the Cervical Midline. F=women and M=men.

Other investigated correlations had the following results: height and diameter ( $p=0.72$ ), weight and vein distance to the cervical midline ( $p=0.84$ ), sex and number of AJVs ( $p=0.37$ ), height and number of AJVs ( $p=0.76$ ), weight and distance between AJVs (Linear regression,  $p=0.52$ ), weight and number of anastomoses ( $p=0.63$ ), age and vein path ( $p=0.45$ ).

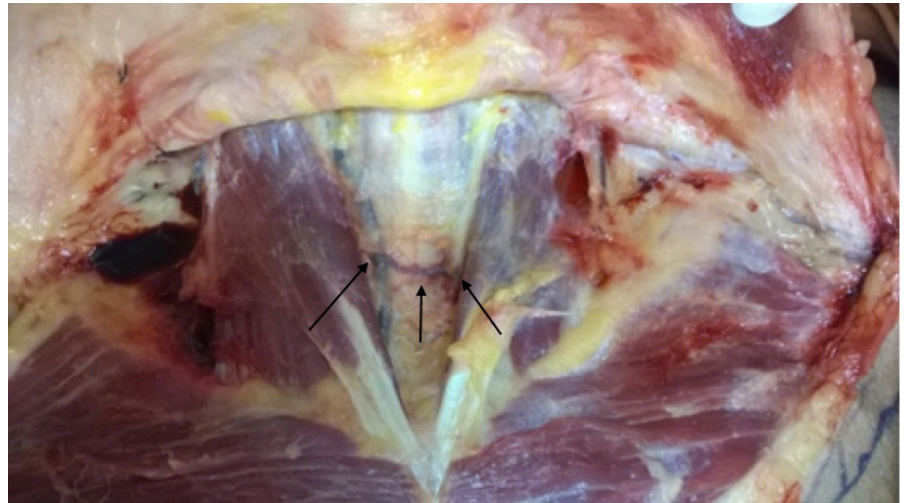
### Discussion

Our main findings include: anatomical variations in the AJVs were observed in 30% of the dissections; there is a possible correlation between sex and

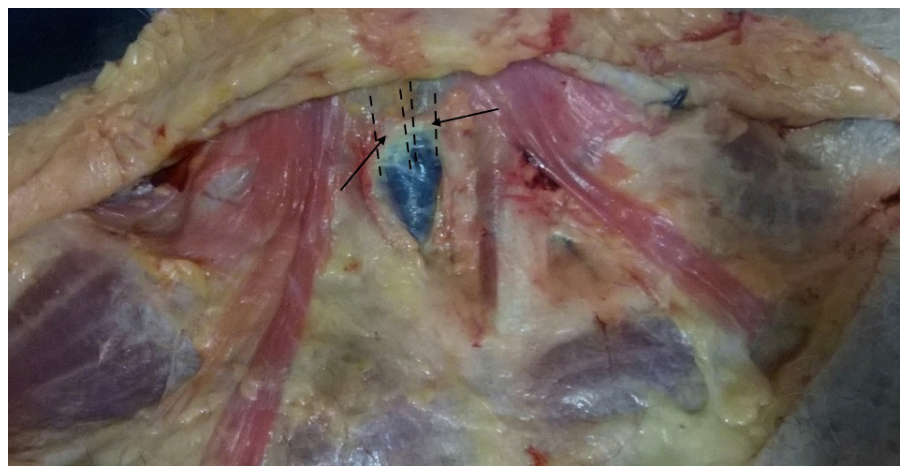distance from the veins to the cervical midline. This correlation, although not statistically significant, suggests that AJVs are located closer to the cervical midline in men than in women.

In most dissections, two AJVs (Figures 4 and 5) were observed, corroborating the literature<sup>2,3</sup>. We also found necks with only one AJV (Figure 6), usually overlapping the cervical midline, as also described in a previous study<sup>1</sup>. Cases with three and four AJVs were also observed (Figures 7 and 8). To the best of our knowledge, such large number of variations has never been described in the literature.

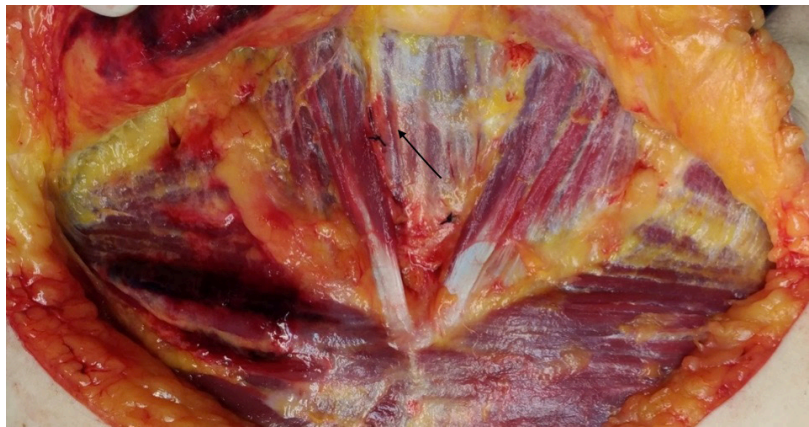
The distance from the veins to the cervical midline in this study was, in most cases, < 10 mm, whereas they have been described as more lateral in the literature<sup>2</sup>. In 60% of the cases, the diameter was <5 mm; so, as described,



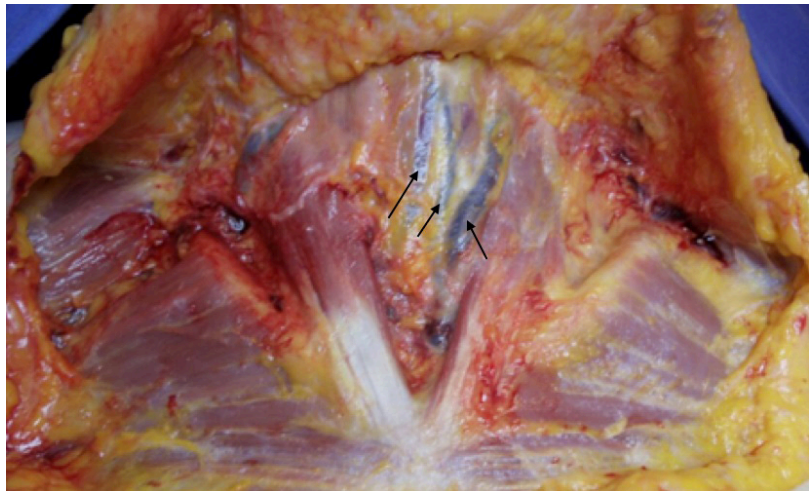
**Figure 4.** Right anterior jugular vein and left anterior jugular vein with similar diameter and H-shaped anastomosis.



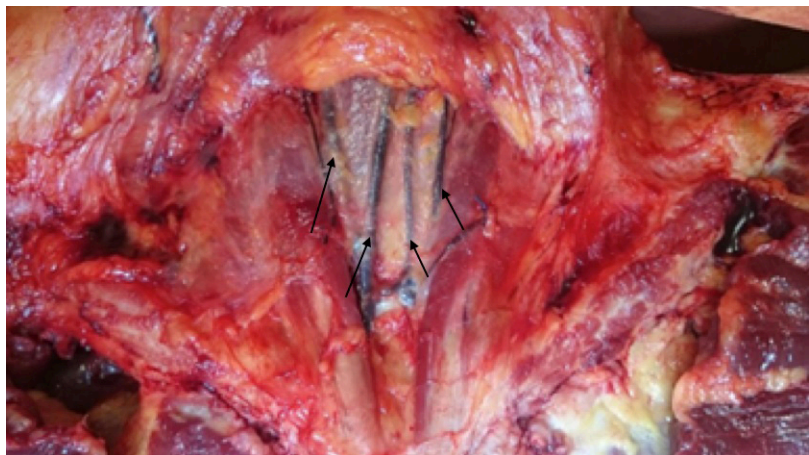
**Figure 5.** Two anterior jugular veins with large diameter over the cervical midline.



**Figure 6.** One anterior jugular vein on the right side.



**Figure 7.** Three anterior jugular veins with various diameters predominantly located on the cervical midline.



**Figure 8.** Four anterior jugular veins communicating through the jugular venous arch near the suprasternal space.

these are usually veins of smaller diameter, although it should be noted that in a significant number of cases they may be found with larger diameters. When anastomoses were present (<30% of the cases), they were mostly H-shaped, thus compromising the medial region of the anterior portion of the neck.

Although 30 cadavers may seem a small sample size for anatomical studies, this number has been proved representative for an initial evaluation in previous studies conducted by our research group<sup>8-10</sup>. Our findings show a high frequency of anatomical variations of the AJVs, mainly related to number and location. The results also show that it is not unusual for those vessels to compromise the cervical midline, which is a commonly accessed region when performing cervical surgeries such as tracheostomies and thyroidectomies. No statistically significant correlation was found between anthropometric factors and AJV anatomy and syntopy; therefore, it is reasonable to always be precautious when dissecting a neck during surgery.

## Conclusion

There are no patterns of variation of the anatomy of the jugular veins influenced by anthropometric factors and comorbidities. Anterior jugular veins (AJVs) were always present, and the configuration most commonly found was two veins, each <5 mm in diameter. AJVs were less than 10 mm away from the cervical midline, and when they presented anastomosis, it was H-shaped in most cases.

## References

1. Paraskevas G, Natsis K, Ioannidis O, Kitsoulis P, Anastasopoulos N, Spyridakis I. Multiple variations of the superficial jugular veins case report and clinical relevance. *Acta Medica (Hradec Kralove)*. 2014;57(1):34-7. <http://dx.doi.org/10.14712/18059694.2014.7>. PMID:25006662.
2. Drake RL, Vogl AW, Mitchell AWM. Cabeça e pescoço. In: Drake RL, Vogl AW, Mitchell AWM, editors. *Gray's: anatomia clínica para estudantes*. 3rd ed. Rio de Janeiro: Elsevier; 2015. p. 837-1129.
3. Moore KL, Dalley AF, Agur MRA. Pescoço. In: Moore KL, Dalley AF, Agur MRA, editors. *Anatomia orientada para a clínica*. 5. ed. Rio de Janeiro: Guanabara-Koogan; 2007. p. 970-1032.
4. Nayak BS. Surgically important variations of the jugular veins. *Clin Anat*. 2006;19(6):544-6. <http://dx.doi.org/10.1002/ca.20268>. PMID:16372344.
5. Karapantzou I, Zarogoulidis P, Charalampidis C, Karapantzou C, Kioumis I, Tsakiridis K, Mpakas A, Sachpekidis N, Organtzis J, Porpodis K, Zarogoulidis K, Pitsiou G, Zissimopoulos A, Kosmidis C, Fouka E, Demetriou T. A rare case of anastomosis between the external and internal jugular veins. *Int Med Case Rep J*. 2016;9:73-5. PMID:27051321.
6. Schummer W, Schummer C, Bredle D, Fröber R. The anterior jugular venous system: variability and clinical impact. *Anesth Analg*. 2004;99(6):1625-9. <http://dx.doi.org/10.1213/01.ANE.0000138038.33738.32>. PMID:15562044.

**\*Correspondence**

Lucas Albuquerque Chinelatto  
Universidade de São Paulo (USP),  
Faculdade de Medicina (FM)  
LIM 02, Av. Dr. Arnaldo, 455,  
Pacaembu  
CEP: 01246-903, São Paulo (SP), Brasil  
+55 (11) 9-99625-2994  
E-mail: l.chinelatto@fm.usp.br

**Author information**

FCH - Professor, Faculty of Medicine,  
University of São Paulo (FMUSP).  
LMPS - RN, School of Nursing,  
University of São Paulo (EE-USP). RAM  
- PhD, Faculty of Medicine, University  
of São Paulo (FMUSP). BDSS - RN,  
School of Nursing, University of São  
Paulo (EE-USP). FEA - Professor,  
Faculty of Medicine, University of São  
Paulo (FMUSP). BBCC - MD, Hospital  
Governador Celso Ramos. LAC -  
MBBS, Faculty of Medicine, University  
of São Paulo (FMUSP). ALJ - Professor,  
Faculty of Medicine, University of São  
Paulo (FMUSP).

7. Shenoy V, Saraswathi P, Raghunath G, Karthik JS. Double external jugular vein and other rare venous variations of the head and neck. *Singapore Med J*. 2012;53(12):e251-3. PMID:23268166.
8. Hojaij FC, Kogima RO, Moyses RA, Akamatsu FE, Jacomo AL. Morphometry and frequency of the pyramidalis muscle in adult humans: a pyramidalis Muscle's anatomical analysis. *Clinics (São Paulo)*. 2020;75:e1623. <http://dx.doi.org/10.6061/clinics/2020/e1623>. PMID:32667491.
9. Barros ACSD, Mori LJ, Nishimura D, Jacomo AL. Surgical anatomy of the internal thoracic lymph nodes in fresh human cadavers: basis for sentinel node biopsy. *World J Surg Oncol*. 2016;14(1):135. <http://dx.doi.org/10.1186/s12957-016-0897-2>. PMID:27129460.
10. Saleh SO, Hojaij FC, Itezeroti AM, Camargo CP, Saleh KS, Andrade MFC, Akamatsu FE, Jacomo AL. Level VI lymph nodes: an anatomic study of lymph nodes located between the recurrent laryngeal nerve and the right common carotid artery. *Rev Col Bras Cir*. 2018;45(6):e1972. <http://dx.doi.org/10.1590/0100-6991e-20181972>. PMID:30517357.



### Appendix 1. Instrument.

#### FORM FOR DATA COLLECTION ON ANTERIOR JUGULAR VEINS

Identification: \_\_\_\_\_

Age: \_\_\_\_\_ Height: \_\_\_\_\_ m

Ethnicity: \_\_\_\_\_ Weight: \_\_\_\_\_ kg

Gender: ( ) male ( ) female

Comorbidities: \_\_\_\_\_

Medication used: \_\_\_\_\_

Smoker: ( ) Yes ( ) No Alcoholic: ( ) Yes ( ) No

Number of Anterior Jugular Veins: \_\_\_\_\_

Path of Anterior Jugular Veins: \_\_\_\_\_

Distance from the Anterior Jugular Veins to the cervical midline:

( ) <10 mm ( ) >10 mm

Distance between Anterior Jugular Veins: \_\_\_\_\_mm

Diameter of the Anterior Jugular Veins: ( ) <5 mm ( ) >5 mm

Presence of anastomosis: ( ) Yes ( ) No

If so, which type? ( ) H-shaped ( ) N-shaped ( ) Y-shaped

Number of anastomoses: ( ) 0 ( ) 1 ( ) 2 ( ) More

Position of anastomosis: ( ) Superiorly ( ) Medially ( ) Inferiorly

\*Presence of Jugular Venous Arch: ( ) Yes ( ) No

\*Location of the Jugular Venous Arch: \_\_\_\_\_

\*Change in thyroid volume? \_\_\_\_\_

\*Presence of nodules: ( ) Yes ( ) No

\*If so, where? \_\_\_\_\_

Items marked with \* will only be filled out when possible.