



CASE REPORT

Combination of surgical techniques and reconstructive devices as an alternative treatment after fibula free flap mandibular reconstruction failure: a case report

Beatrice Mitye Ogusco^{1,2*}, Luiza Miguel Simonetti², André Sakima Serrano³, Luiz Carlos Ishida⁴, Rafael Tutihashi^{4,5}, Dorival Carlucci⁶, Sérgio Gonçalves^{3,6,7}

¹Centro Odontológico da Polícia Militar do Estado de São Paulo, Departamento de Cirurgia, São Paulo, SP, Brasil

²Universidade São Camilo, Faculdade de Medicina, São Paulo, SP, Brasil

³Hospital Israelita Albert Einstein, Cirurgia Craniomaxilofacial, São Paulo, SP, Brasil

⁴Universidade de São Paulo, Faculdade de Medicina, Hospital das Clínicas, Disciplina de Cirurgia Plástica, São Paulo, SP, Brasil

⁶Instituto do Câncer do Estado de São Paulo, Disciplina de Cirurgia de Cabeça e Pescoço, São Paulo, SP, Brasil

⁵Instituto do Câncer do Estado de São Paulo, Disciplina de Cirurgia Plástica, São Paulo, SP, Brasil

⁷Universidade de São Paulo, Faculdade de Medicina, Hospital das Clínicas, Disciplina de Cirurgia de Cabeça e Pescoço, São Paulo, SP, Brasil

Abstract

Loss of mandibular continuity and functionality in cancer patients undergoing extensive mandible resections is challenging. In these situations, the gold standard treatment is fibula free flap reconstruction. The major challenge occurs when there is a failure of the transplanted fibula. Here we report the case of a patient who underwent right hemimandibulectomy with disarticulation and immediate mandibular reconstruction with a fibula free flap. Subsequently, the flap viability was lost, and there was necrosis of the transplanted bone segment in the short-term follow-up. Considering the best form of rehabilitation for the patient, minimizing the risks of loss and optimizing the reconstructive quality, we opted to install a customized prosthesis including a condyle-cavity joint component associated with a new free flap and subsequent rehabilitation of the dental occlusion with an implant-supported fixed prosthesis.

Keywords: free tissue flaps; head and neck neoplasms; mandibular prosthesis implantation; mandibular reconstruction; microsurgery; reconstructive surgical procedures.

How to cite: Ogusco BM, Simonetti LM, Serrano AS, Ishida LC, Tutihashi R, Carlucci D, Gonçalves S. Combination of surgical techniques and reconstructive devices as an alternative treatment after fibula free flap mandibular reconstruction failure: a case report. Arch Head Neck Surg. 2022;51:e20220002. <https://doi.org/10.4322/ahns.2022.0002>

Introduction

Oncological patients undergoing segmental resection of the mandible often suffer from sequelae brought about by the treatment offered. Loss of mandibular continuity has harmful effects on masticatory mechanics; loss of bone support causes underlying soft tissue structures to contract, potentially resulting in oral incompetence; dysarthria and disorders in the oral phase of swallowing may occur; in addition to other functional problems that arise

Financial support: None.
Conflicts of interest: No conflicts of interest declared concerning the publication of this article.
Submitted: January 24, 2022.
Accepted: March 06, 2022.
The study was carried out at Hospital Israelita Albert Einstein, São Paulo, SP, Brasil.



Copyright Ogusco et al. This is an Open Access article distributed under the terms of the Creative Commons Attribution License, which permits unrestricted use, distribution, and reproduction in any medium, provided the original work is properly cited.

and/or are exacerbated by postoperative radiotherapy, when indicated. Facial contour deformity is another important factor that has a significant impact on the patient's self-image and social life.

Historically, large mandibular defect reconstructions have been a challenge for surgeons. Microsurgical flaps were first described in 1975 by Taylor¹. In 1989, Hidalgo et al. were the first to report fibular bone transfer to reconstruct a mandible segmental defect¹. Over time, different modalities of microsurgical reconstruction have performed best at restoring large mandibular arch defects. This technique has drastically changed the approach and expectations of patients affected by mandible neoplasms, and they can even be rehabilitated with osseointegrated dental implants that reestablish effective masticatory capacity¹. The osteogenic potential of the transferred bone is preserved with osteomyocutaneous transplantation, which plays an active role in osteosynthesis with the native mandible, enabling complete functional rehabilitation².

However, even with the advanced development of reconstructive surgical techniques, the success of microsurgical transplantation can still be limited or hampered by numerous factors: deficient or sick microcirculation, causing damage to the vascularization of the bone tissue; transplant contamination by dehiscence or continuities with natural cavities (mouth, nose, paranasal sinuses); formation of cervical hematomas that can compress the vascular pedicle; excessive and untimely handling during adaptation of the surgical specimen to the recipient site (inset of the transplant)^{3,4}. In this paper, we report a combination of surgical techniques and reconstructive devices used as an alternative treatment after failure of microvascularized osteomyocutaneous fibula flap in mandibular reconstruction.

Case report

Male patient ASB, Caucasian, aged 58 years, underwent right hemimandibulectomy with disarticulation, extended to the contralateral parasymphyseal region as a result of osteogenic osteosarcoma of the mandible body. Immediate mandibular reconstruction was performed using a right microvascularized osteomyocutaneous fibula flap. The patient was followed up without complications, and was discharged from hospital on the 7th postoperative day.

On the 15th postoperative day, he presented signs of suffering from the transplant skin island, and debridement of the devascularized epithelial tissue was indicated, maintaining muscle coverage over the fibular bone tissue. Second intention mucosal epithelization occurred without major complications.

On the 40th postoperative day, the patient reported secretion through a tiny fistulous orifice close to the cervical and intraoral surgical access. After physical examination, purulent secretion outflow through the fistula was confirmed. Empirical antibiotic therapy was introduced, and an imaging exam was requested. Computed tomography (CT) revealed synthesis device failure and radiolucency areas in the fibula, suggesting loss of transplanted bone tissue viability.

A new approach and local surgical debridement were indicated to assess flap viability. Venous thrombosis of the vascular pedicle and necrosis of the entire transplanted fibular segment were identified. We opted to remove all necrotic tissue, wash the surgical wound abundantly, and install a mandibular reconstructive plate to maintain facial contour for subsequent definitive mandibular reconstruction.

The patient evolved with facial contour deformity, significant masticatory and phonatory functional deficit, and impossibility of prosthetic rehabilitation (Figure 1).

Four months later, we proposed to install a customized mandibular prosthesis, including the condyle-cavity joint component associated with a new osteomyocutaneous flap of the contralateral fibula to provide adequate bone substrate for osseointegrated dental implants and subsequent complete and definitive prosthetic rehabilitation (Figure 2). Four osseointegrated dental implants were installed for prosthetic rehabilitation through an implant-supported hybrid fixed partial prosthesis corresponding to the resected dental segment. A 6-year postoperative follow-up of implant placement showed clinical and radiographic stability of the mandibular reconstruction and implant-supported prosthetic rehabilitation (Figure 3).

Discussion

Mandible segmental defects caused by oncological resection surgery can lead to disfiguring and disabling conditions. Restoring facial function and esthetics become a challenge in mandibular reconstruction, especially when the temporomandibular joint (TMJ) is involved. Currently, there are several reconstructive options to restore mandibular continuity, and microvascularized fibula flap is the gold standard in these situations. Several studies have reported a flap survival rate >95%¹. The fibula can be osteotomized in multiple segments to provide the new mandibular contour, and fibular bone

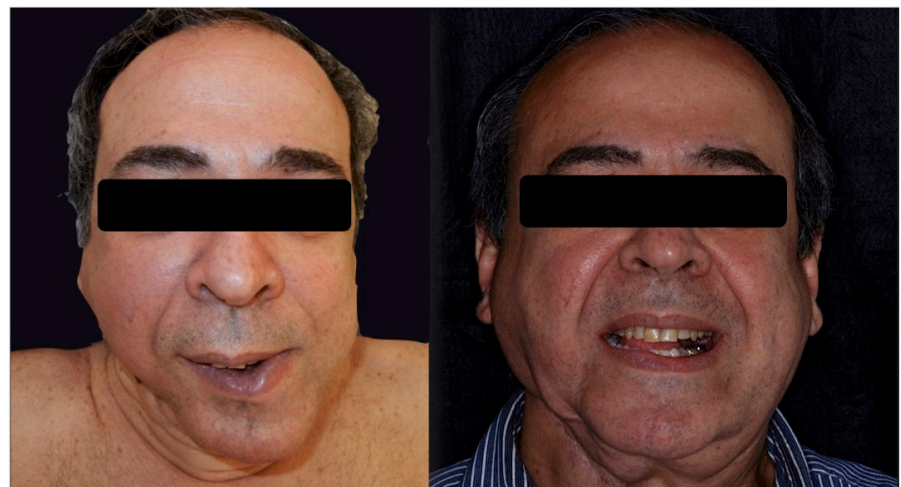

Figure 1. Pre- and post-operative frontal photographs. Adequate mandibular positioning is observed, providing a more esthetic and symmetrical facial contour.

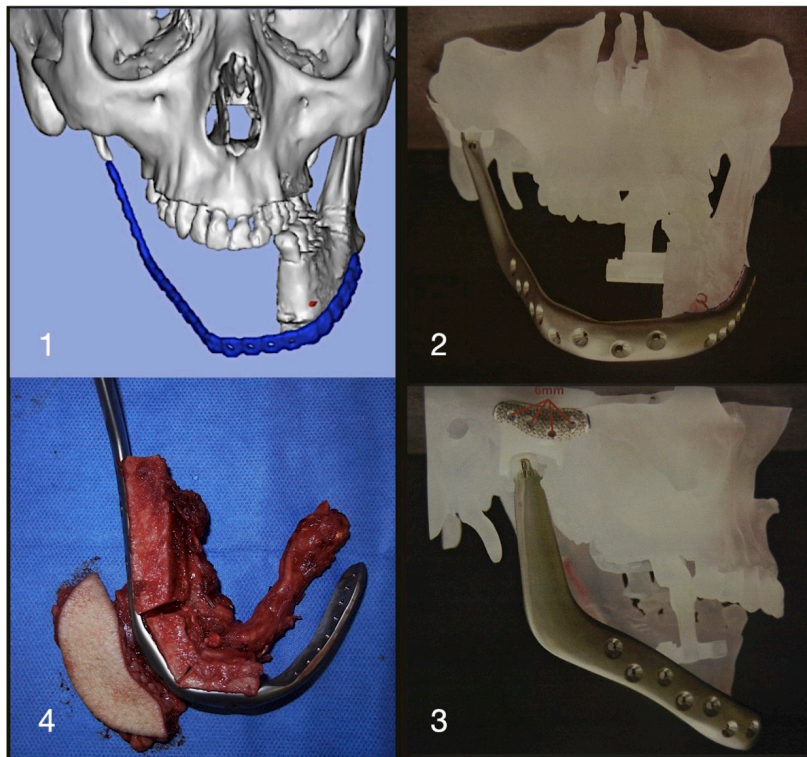


Figure 2. 1 - Virtual planning preoperative image showing the reconstructive plate position and deviation due to muscle action. 2 and 3 - Planning of the three-dimensional prosthetic devices (condyle cavity). 4 - Transoperative: fibular bone flap position in the milled portion of the customized prosthesis.

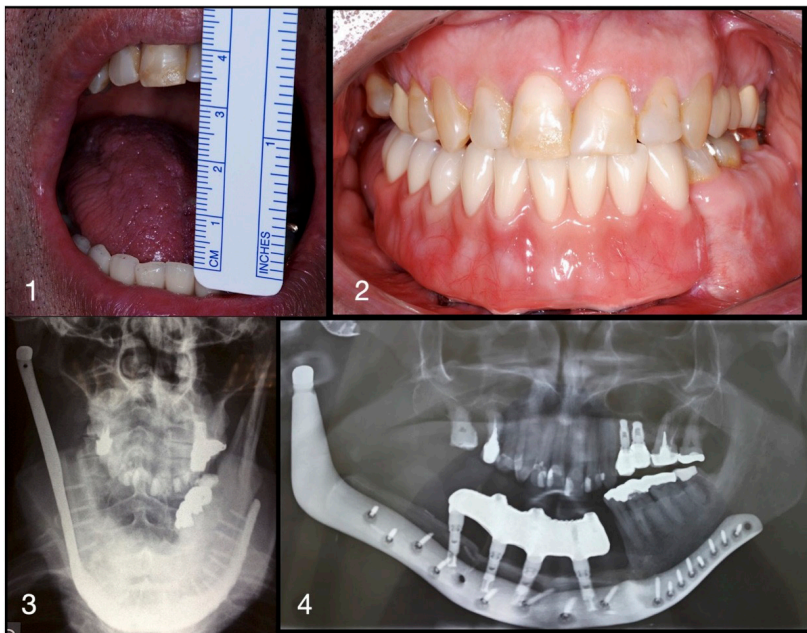

Figure 3. 1 - Oral opening (35 mm) with no joint deviation. 2 - Final occlusion with implant-supported prosthesis. 3 - Postoperative radiography: adequate condylar symmetry. 4 - Panoramic radiography: after six months of follow-up.

architecture is similar to that of the mandible; this will provide greater strength and the necessary bone tissue to install dental implants¹.

TMJ resection, together with mandibular segment, results in malocclusion, mastication difficulty, trismus, and posterior mandibular height loss; its reconstruction is a great challenge¹. Reestablishing an adequate posterior mandibular height and a functional joint that allows maintenance of a range of motion is quite difficult using only bone grafts/flaps. Customized prosthetic devices are a great tool for the surgeon, being extremely useful in bone tumors with TMJ involvement¹. Thus, for joint reconstruction, customized material is the best choice to obtain results as close as possible to the desired result, since an ideal reconstruction includes mobility without interferences, while the full support of the masticatory curtains is desired, avoiding the possibility of bone ankylosis and offering a better facial contour. Virtual planning technological advances have allowed the machining of customized three-dimensional prostheses, enabling better adaptation of the grafted/transplanted bone to the prosthetic device. Milling the prosthesis inner surface with flat areas and sharp angles provides adequate accommodation of the fibular bone flap, as observed in this case report. Furthermore, a three-dimensional virtual image of the fibula allows the creation of templates to perform osteotomies in pre-established locations, saving surgical time and maximizing the predictability of contact between the bone stumps and, consequently, adequate bone union.

Causes of microsurgical flap failures include insufficient anastomosis, venous congestion, arterial obliteration, vascular spasm, postoperative bleeding, and coagulopathies. Vascular deficit and venous thrombosis, particularly, are the main reasons for flap failure. Pedicle venous thrombosis has been reported as the main reason for salvage procedures, and can be considered the weakest vascular component. Venous anastomosis is susceptible to spasms, compacting by hematoma or edema and folding by flexion or extension of the head and/or neck postoperatively. This leads to venous congestion and, eventually, thrombosis^{3,4}.

The highest failure rates in reconstructed defects were observed in cases that included the condyle, although the finding was not statistically significant in the study by Verhelst et al.³ Those authors believe that this trend can be attributed to the fact that the vascular pedicle is more prone to folds because of its position in the reconstruction of defects that extend to the condyle³. In this case report, failure of the first mandibular reconstruction was due to late insufficiency in the flap vascularization, first with loss primarily of soft tissue and then of all bone tissue.

Because of the unacceptability of another possible reconstructive failure, we chose to perform a smaller bone transplant with a minimum of osteotomies and folds to minimize possible risk factors. Furthermore, the simultaneous choice of the customized prosthetic device additionally enabled extremely functional joint reconstruction, minimal fibular modeling, and shorter tissue ischemia time, providing a tension-free anastomosis with adequate space for the vascular pedicle and greater predictability of expected results.

The choice for prosthetic reconstruction associated with a microvascularized fibula flap brings another reconstructive advantage: the presence of bone tissue allows the installation of dental implants and complete oral rehabilitation, entirely restoring the masticatory, phonatory and esthetic function.

Currently, new prosthetic devices for mandibular reconstructions with dental implants previously coupled to the metallic structure have been reported in the literature, as by Lee et al.⁵ Its use has been justified by a reduction in operative time, as it eliminates the need for a bone tissue donor site and provides better esthetic results compared with an autologous reconstruction of the fibula, radius, or scapula. However, dental implants directly coupled to mandibular prosthetic devices expose the metallic material to the oral environment through the peri-implant sulcus. There are no reports in the literature proving that the tissue adheres to the metallic device and that such an interface is sealed; thus, an infectious dissemination pathway remains throughout the prosthetic device, resulting in biofilm formation, a chronic infection that can lead to prosthesis loss and reconstructive failure. Therefore, to date, the use of such devices has not been justified because of a simplification of the technique and because there are no robust studies with long-term follow-up on this “new” rehabilitation modality.

The current gold standard to reconstruct extensive mandible defects is microvascularized fibula flap, which allows restoration of mandibular continuity and function. However, when failures occur, the difficulty in obtaining optimal results is increased. The possibility of using customized devices associated with traditional reconstructive techniques brings benefits in terms of saving surgical time, ensuring greater predictability of the result, and allowing a safer and much more complete functional restoration, which can be a great option in selected cases.

References

1. Bak M, Jacobson AS, Buchbinder D, Urken ML. Contemporary reconstruction of the mandible. *Oral Oncol.* 2010;46(2):71-6. <http://dx.doi.org/10.1016/j.oraloncology.2009.11.006>. PMID:20036611.
2. Urken ML, Buchbinder D, Costantino PD, Sinha U, Okay D, Lawson W, Biller HF. Oromandibular reconstruction using microvascular composite flaps: report of 210 cases. *Arch Otolaryngol Head Neck Surg.* 1998;124(1):46-55. <http://dx.doi.org/10.1001/archotol.124.1.46>. PMID:9440780.
3. Verhelst P-J, Dons F, Van Bever P-J, Schoenaers J, Nanhekhan L, Politis C. Fibula free flap in head and neck reconstruction: identifying risk factors for flap failure and analysis of postoperative complications in a low volume setting. *Craniofac Trauma Reconstr.* 2019;12(3):183-92. <http://dx.doi.org/10.1055/s-0038-1651515>. PMID:31428242.
4. Knitschke M, Sonnabend S, Bäcker C, Schmermund D, Böttger S, Howaldt HP, Attia S. Partial and total flap failure after fibula free flap in head and neck reconstructive surgery: retrospective analysis of 180 flaps over 19 years. *Cancers.* 2021;13(4):865. <http://dx.doi.org/10.3390/cancers13040865>. PMID:33670721.

***Correspondence**

Beatrice Mitye Ogusco
Centro Odontológico da Polícia
Militar do Estado de São Paulo,
Departamento de Cirurgia
Rua Doutor Jorge Miranda, 346, Luz
CEP 01106-000, São Paulo (SP), Brasil
Tel.: +55 (11) 976689910
E-mail: beatriceogusco@gmail.com

5. Lee YW, You HJ, Jung JA, Kim DW. Mandibular reconstruction using customized three-dimensional titanium implant. Arch Craniofac Surg. 2018;19(2):152-6. <http://dx.doi.org/10.7181/acfs.2018.01830>. PMID:29921117.

Authors information

BMO - Oral and Maxillofacial Surgery, Centro Odontológico da Polícia Militar do Estado de São Paulo; Medical student, Faculty of Medicine, Universidade São Camilo. LMS - Medical student, Faculty of Medicine, Universidade São Camilo. ASS - Oral and Maxillofacial Surgery, Hospital Israelita Albert Einstein. LCI and RT - Plastic Surgery - Reconstructive Surgery, Hospital das Clínicas, Faculty of Medicine, University of São Paulo. DC - Head and Neck Surgery, Hospital das Clínicas, Faculty of Medicine, University of São Paulo. SG - Head and Neck Surgery, Hospital das Clínicas, Faculty of Medicine, University of São Paulo; Oral and Maxillofacial Surgery, Hospital Israelita Albert Einstein.