



**CASE REPORT**

# Clear cell change in mucocele: an unusual histological variant

Camilo Andrés Pérez Montiel<sup>1\*</sup>, Gabriel Jaime Varela Aguirre<sup>2</sup>

## Abstract

Oral mucocele (OM) with clear cell change is a rare histological variant that can generate diagnostic difficulties and must be differentiated from benign, malignant and metastatic neoplasms that have this histological pattern. We present the case of a 27-year-old woman with OM with clear cell change in which the complete medical history, histopathological evaluation and immunohistochemical studies led to a correct diagnosis.

**Keywords:** Mucocele; Otorhinolaryngologic Neoplasms; Immunohistochemistry.

**How to cite:** Pérez Montiel CA, Varela Aguirre GJ. Clear cell change in mucocele: an unusual histological variant. Arch Head Neck Surg. 2021;50:e20210015. <https://doi.org/10.4322/ahns.2021.0015>

## Introduction

Oral mucocele (OM) is a reactive lesion caused by mucus extravasation secondary to trauma to the minor salivary gland ducts. This generates the formation of granulation tissue with abundant foamy macrophages<sup>1-3</sup>. OM has been reported in patients of all ages, but is more common in children and young adults. It does not have a predilection for gender and the most common location is on the mucosa of the lower lip. Other presentation sites include the floor of the mouth, the ventral aspect of the tongue, the soft palate, and the retromolar pad<sup>1</sup>. OM has infrequent histological variants, such as superficial, with myxoglobulosis-like change and with papillary synovial metaplasia-like change<sup>1,2</sup>. The objective of the following manuscript is to present the case of a 32-year-old woman with OM with clear cell change, this histological variant must be differentiated from benign and malignant neoplasms with clear cells, such as salivary, squamous, melanocytic and metastatic tumors.

## Case report

A 27-year-old woman who consulted for a painless and sessile nodule on the mucosa of the lower lip with 1 month duration. The patient did not report any antecedents in the medical history and the physical examination did not reveal other alterations. The lesion was resected. In the histopathological evaluation, oral mucosa was observed without alterations in the squamous epithelium (Figure 1A). In the stroma, a diffuse population of clear cells was identified that at higher magnification had hyperchromatic nuclei and

<sup>1</sup>Universidad de Cartagena, Cartagena de Indias, Colombia

<sup>2</sup>Hospital Pablo Tobón Uribe, Medellín, Colombia

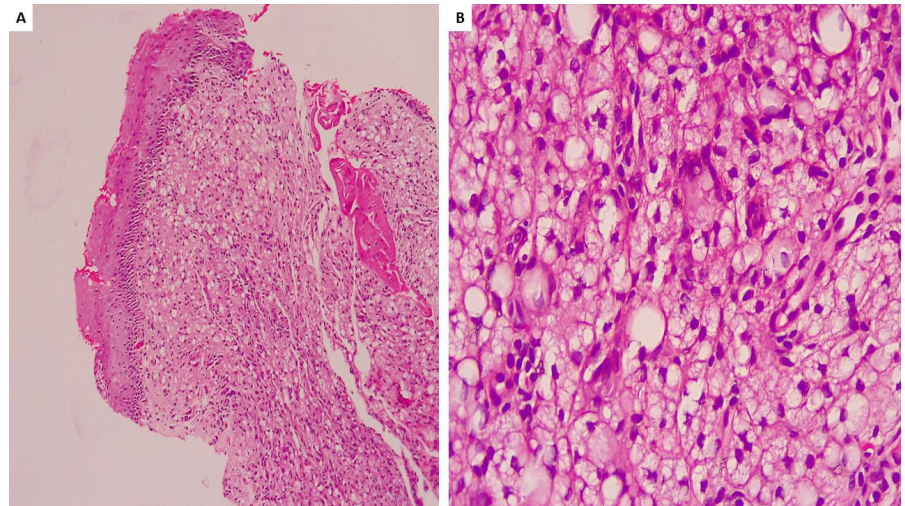
**Financial support:** None.  
**Conflicts of interest:** No conflicts of interest declared concerning the publication of this article.  
**Submitted:** August 30, 2021.  
**Accepted:** September 23, 2021.

The study was carried out at Clínica Aurora - Centro Especializado en Cáncer de Piel, Medellín, Colombia.

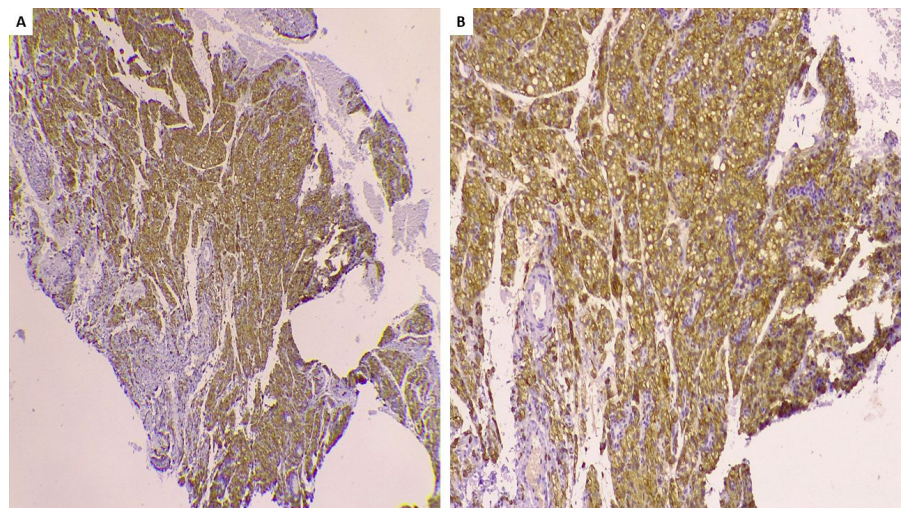


Copyright Pérez Montiel et al. This is an Open Access article distributed under the terms of the Creative Commons Attribution License, which permits unrestricted use, distribution, and reproduction in any medium, provided the original work is properly cited.

vacuolated cytoplasm; other cells had signet ring cell morphology (Figure 1B). Immunohistochemical stains were performed that showed strong and diffuse positivity for CD163 and CD68 (Figure 2A and B). Stains with AE1/AE3, SOX10, S100 and p63 were negative, with which the diagnosis of OM with clear cell change was determined.



**Figure 1. A** - Photomicrograph showing oral mucosa lined by squamous epithelium without dysplasia. A diffuse population of cells with clear cytoplasm is identified in the stroma. H / E, 10x. **B** - Photomicrograph showing cells with vacuolated cytoplasm and hyperchromatic nuclei. Others have signet ring cell morphology. H / E, 40x.



**Figure 2. A** - Photomicrograph showing strong and diffuse positive staining with CD163. Immunohistochemistry, 4x. **B** - Photomicrograph showing strong and diffuse positive staining with CD68. Immunohistochemistry, 10x

## Discussion

OM does not usually present diagnostic difficulties because histopathological findings are relatively common and are characterized by extravasation of mucus associated with granulation tissue and macrophages. However, some

may exhibit a wide morphological diversity, which generates diagnostic difficulties. The less common histopathological variants are superficial, with myxoglobulosis-like change, with papillary synovial metaplasia-like change and with clear cell change<sup>1,2</sup>. OM with clear cell change is a rare variant, B.V. de Brito Monteiro et al evaluated 667 cases of OM and found that only 11 cases (1.64%) had a clear cell change<sup>3</sup>.

OM with clear cell change must be distinguished from neoplastic pathologies that may have this morphology and that carry a poor prognosis for the patient. The differential diagnosis includes salivary gland, melanocytic, squamous, and metastatic tumors. Most of these have specific histopathological characteristics, however, on some occasions, immunohistochemical staining and a complete medical history must be performed to achieve a correct diagnosis.

Salivary gland neoplasms that may have clear cell change are myoepithelioma, oncocytoma, mucoepidermoid carcinoma, myoepithelial carcinoma, acinar cell carcinoma, and clear cell carcinoma. By immunohistochemistry, all previous neoplasms are positive for cytokeratins, compared to OM, which is negative<sup>2,4</sup>.

Melanocytic neoplasms that have clear cells such as balloon cell nevus and balloon cell malignant melanoma can occur on the skin of the head and neck, however, they are uncommon in the oral cavity. Histologically, melanocytes, in addition to having clear and foamy cytoplasm, may present occasional pigmentation and areas with typical melanocytes associated with cytological atypia and mitosis figures, which helps to guide the diagnosis. In immunohistochemistry, melanocytic cells can be positive for S100, SOX10, HMB45 and Melan A. In this case, melanocytic markers were negative<sup>2</sup>.

Squamous cell carcinoma with clear cells is another of the differential diagnoses to consider, this neoplasm is positive for cytokeratins and squamous cell markers such as p63 and p40. Metastatic neoplasms such as clear cell carcinoma of the kidney, prostate, thyroid, small intestine, and lung can also metastasize to the oral cavity<sup>5</sup>. In general, these neoplasms are positive for cytokeratins and other immunohistochemical markers depending on the organ of origin, such as PAX8, RCC, CAIX, PSA, NKX3.1, racemase, TTF-1, CK7, CK20 and Napsin A.

Clear cells can generate difficulties in histopathological diagnosis because there is a wide variety of reactive pathologies, benign and malignant neoplasms that can have this morphology. A correct clinical history, histopathological evaluation and an immunohistochemical panel can avoid errors in diagnosis.

## References

1. Chi AC, Lambert PR 3rd, Richardson MS, Neville BW. Oral mucoceles: a clinicopathologic review of 1,824 cases, including unusual variants. *J Oral Maxillofac Surg.* 2011;69(4):1086-93. <http://dx.doi.org/10.1016/j.joms.2010.02.052>. PMID:20708324.
2. Piña AR, Almeida LY, Andrade BA, León JE. Clear cell change in a lower lip mucocele. *J Oral Maxillofac Pathol.* 2013;17(2):318. <http://dx.doi.org/10.4103/0973-029X.119776>. PMID:24250103.

**\*Correspondence**

Camilo Andrés Pérez Montiel  
Universidad de Cartagena  
Hospital Universitario del Caribe,  
Laboratorio de Patología, Barrio  
Zaragocilla, ZIP code 130014  
Cartagena de Indias, Colombia  
Tel.: +57 316 5781537  
E-mail: capm2908@gmail.com

**Authors information**

CAPM: MD, Pathology Resident,  
Universidad de Cartagena. GJVA:  
MD, Oncologist Pathologist,  
Dermatopathologist, Hospital Pablo  
Tobón Uribe.

3. Brito Monteiro BV, Bezerra TM, da Silveira ÉJ, Nonaka CF, da Costa Miguel MC. Histopathological review of 667 cases of oral mucoceles with emphasis on uncommon histopathological variations. *Ann Diagn Pathol.* 2016;21:44-6. <http://dx.doi.org/10.1016/j.anndiagpath.2016.02.001>. PMID:27040930.
4. Bastaki J, Summersgill K. Signet-ring cell (mucin-producing) adenocarcinoma of minor salivary glands: report of a case. *Oral Surg Oral Med Oral Pathol Oral Radiol Endod.* 2010;110(4):e33-6. <http://dx.doi.org/10.1016/j.tripleo.2010.05.066>. PMID:20868985.
5. Ellis GL. Clear cell neoplasms in salivary glands: clearly a diagnostic challenge. *Ann Diagn Pathol.* 1998;2(1):61-78. [http://dx.doi.org/10.1016/S1092-9134\(98\)80035-X](http://dx.doi.org/10.1016/S1092-9134(98)80035-X). PMID:9845723.