



**CASE REPORT**

# Idiopathic bone cavity mimicking odontogenic tumor - case report

Victor Perez Teixeira<sup>1,2\*</sup>, Nayara Gobara<sup>1</sup>, Rodrigo Alves Ribeiro<sup>1</sup>,  
José Narciso Rosa Assunção Júnior<sup>1</sup>

## Abstract

Idiopathic bone cavity is an intraosseous pseudocyst characterized by an empty or fluid-filled cavity, which most commonly affects the jaw. A male patient, 24 years of age, was referred for evaluation of multilocular radiolucent lesion, circumscribed in the left jaw region, which was identified during a routine radiographic examination. An incisional biopsy was performed, with a diagnostic hypothesis of ameloblastoma, where a small apparent bone fenestration and a complete absence of surgical site contents were observed. The diagnosis for idiopathic bone cavity was established by these transoperative characteristics. Regression of the intraosseous lesion was observed during the clinical and radiographic follow-up.

**Keywords:** jaw neoplasms; jaw diseases; diagnosis; oral.

<sup>1</sup>Universidade Metropolitana de Santos (UNIMES), Faculdade de Odontologia, Santos, SP, Brasil

<sup>2</sup>Universidade Metropolitana de Santos (UNIMES), Faculdade de Medicina, Santos, SP, Brasil

**Financial support:** None.  
**Conflicts of interest:** No conflicts of interest declared concerning the publication of this article.  
**Submitted:** June 14, 2017.  
**Accepted:** December 05, 2017.

The study was carried out at Faculdade de Odontologia, Universidade Metropolitana de Santos (UNIMES), Santos, SP, Brasil.


## Introduction

Idiopathic bone cavity (IBC) is a nonneoplastic pseudocyst. It is more common in young women under 18 years old in the region of the body of the jaw<sup>1,2</sup>.

IBC has been reported in the literature under multiple designations over time, in attempts to correlate it with an etiology that remains unknown, such as: traumatic bone cyst, hemorrhagic bone cyst, idiopathic bone cyst, essential bone cyst, simple bone cyst, solitary bone cyst, extravasation cyst, and progressive bone cyst. Its current classification as a pseudocyst matches the World's Health Organization's (WHO) classification, as this pathology produces an empty or fluid-filled intraosseous cavity<sup>3</sup>.

As it is frequently asymptomatic, IBC is usually identified in routine imaging tests. It is most commonly presented on X-rays as well-defined, unilocular, lucent image in the body of the jaw region. It contours the dental roots, with cortical thinning, but without expansion or perforation<sup>2</sup>. Differential diagnoses are inflammatory periapical cyst and odontogenic keratocyst<sup>4</sup>.

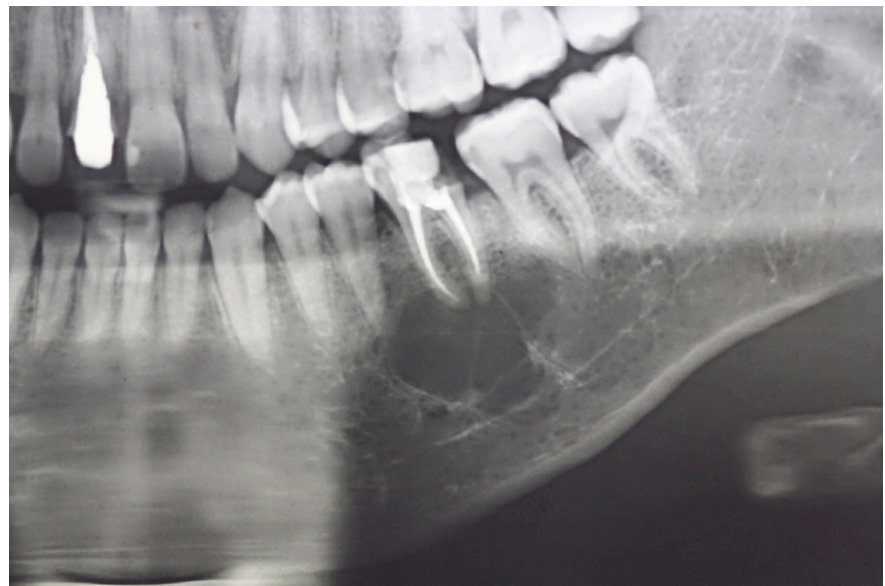
Diagnosis is confirmed during surgery, due to the absence of material for histopathological analysis. The treatment recommended is curettage to fill the cavity with blood and suture. The use of biomaterials and PRP have been described with the objective of accelerating bone formation<sup>4,5</sup>.

 Copyright Teixeira et al. This is an Open Access article distributed under the terms of the Creative Commons Attribution License, which permits unrestricted use, distribution, and reproduction in any medium, provided the original work is properly cited.

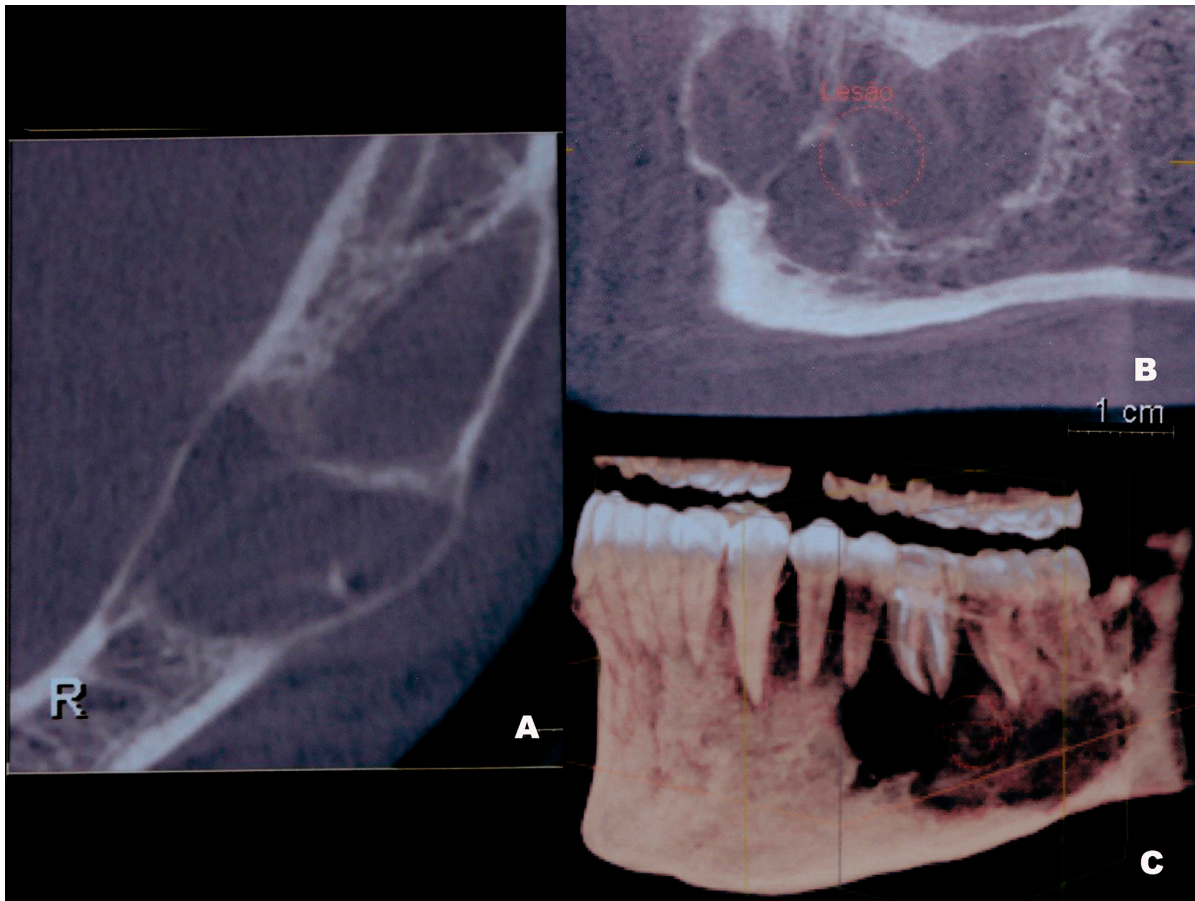
This report aims to present a case of idiopathic bone cavity with unusual radiographic presentation. This paper has been submitted to, and approved by, the Human Research Ethics Committee of UNIMES—CAAE: 64598617.0.0000.5509.

### Case report

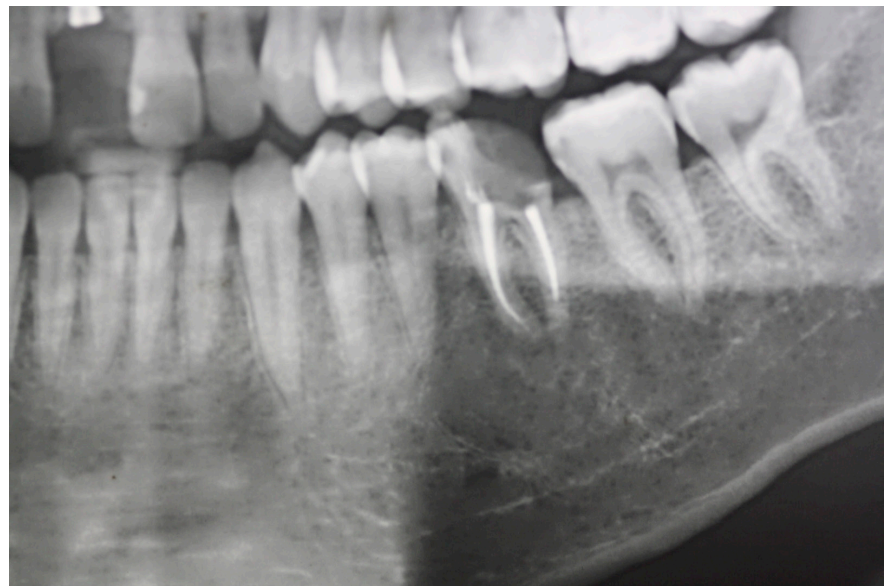
Male patient, 24 years old, brown skin, was referred to Universidade Metropolitana de Santos (UNIMES), the stomatology outpatient clinic of UNIMES. The patient reported that, upon seeing a dental surgeon for extraction of third molars and having a panoramic X-ray done for this purpose, the test revealed a lucent image on the left side of the body of the jaw. The patient reported no history of trauma in the region. An extra-oral physical exam revealed a slight increase of volume and absence of pain upon palpation. The panoramic X-ray revealed a well-defined, multilocular, circumscribed lucent lesion of approximately 2 cm on the left posterior side of the jaw, which touched the root of teeth 35, 36, and 37 without causing resorption (Figure 1). A computed tomography (CT) was ordered, where characteristic intralesional septa were identified, which indicates multilocularity, in addition to cortical expansion (Figure 2). In face of these imaging details, ameloblastoma was the diagnostic hypothesis. During the incisional biopsy, following mucoperiosteal detachment, a small apparent fenestration was observed. We performed an ostectomy, in order to better explore with a curette. All of the walls were investigated, and we found an empty cavity, without membrane or capsule. Due to the absence of materials in the surgical cavity, we intraoperatively diagnosed the idiopathic bone cavity. The patient has been under clinical and radiographic follow-up for 1 year, through which we observe regression of the lesion and bone neoformation (Figure 3).



**Figure 1.** Panoramic X-ray: Lucent and multiloculated image with well-defined edges.



**Figure 2.** Axial view (A), Sagittal reconstruction (B), and 3D view (C) of CT. Multilocular image with vestibular cortical expansion and disclosure of intralesional septa. R: Right.



**Figure 3.** Panoramic X-ray: Follow-up after 1 year showing bone neoformation.

**\*Correspondence**

Victor Perez Teixeira  
Universidade Metropolitana de Santos  
(UNIMES), Faculdade de Odontologia  
Av. Conselheiro Nebias, 536  
CEP 11045-002, Santos (SP), Brasil  
Tel.: +55 (13) 3228-3400  
E-mail: victorpteixeira@hotmail.com

**Authors information**

VPT and RAR - Dentists, Mscs,  
Universidade Metropolitana de  
Santos (UNIMES); NG - Universidade  
Metropolitana de Santos (UNIMES);  
JNRAJ - Dentist, PhD, Universidade  
Metropolitana de Santos (UNIMES).

**Discussion**

The classic radiographic aspect of IBC is that of a well-defined, unilocular, lucent image whose edges reach in between the roots in a wavy pattern<sup>1,3,4</sup>. However, in this case report, the image was lucent, multilocular, circumscribed, well-defined with cortical expansion. These characteristics lead us to a diagnostic hypothesis of a locally aggressive odontogenic tumor; in this case, ameloblastoma.

Its diagnosis can be complex, as there are many lesions with similar clinical and radiographic characteristics. Thus, it is necessary to connect clinical history, physical examination, and imaging tests, besides surgical exploration for a clearer sight. In some cases, these radio- and tomographic aspects may lead to diagnostic hypothesis of odontogenic tumor, more aggressive diseases with high probability of recurrence<sup>2,4</sup>.

Treatment possibilities of maxillo and bone pathologies are wide, and depend on their clinical behavior. On the other hand, odontogenic cysts, in general, are well controlled with surgical resection followed by curettage of walls. Odontogenic tumors such as ameloblastoma are traditionally treated by means of resection<sup>2</sup>. These groups of pathologies, as well as the idiopathic bone cavity, can share the same imaging presentation<sup>4</sup>. Thus, the absence of incisional biopsy can lead to over-indicated and often mutilating treatments with severe aesthetic and functional repercussions caused by negligence of a well-established preoperative diagnosis.

**References**

1. Velez I, Siegel MA, Mintz SM, Rolle R. The relationship between idiopathic bone cavity and orthodontic tooth movement: analysis of 44 cases. *Dentomaxillofac Radiol.* 2010;39(3):162-6. <http://dx.doi.org/10.1259/dmfr/12528297>. PMID:20203278.
2. Resnick CM, Dentino KM, Garza R, Padwa BL. A management strategy for idiopathic bone cavities of the jaws. *J Oral Maxillofac Surg.* 2016;74(6):1153-8. <http://dx.doi.org/10.1016/j.joms.2015.12.014>. PMID:26850870.
3. Rivero ERC, Daltoé FP, Mello FW, de Souza CECP, Grandó LJ. Aspiration and cytological evaluation of idiopathic bone cavities of the jaw. *Tissue Cell.* 2017;49(3):435-9. <http://dx.doi.org/10.1016/j.tice.2017.03.005>. PMID:28366535.
4. You MS, Kim DY, Ahn KM. Surgical management of idiopathic bone cavity: case series of consecutive 27 patients. *J Korean Assoc Oral Maxillofac Surg.* 2017;43(2):94-9. <http://dx.doi.org/10.5125/jkaoms.2017.43.2.94>. PMID:28462193.
5. Tabrizi R, Karagah T, Shahidi S, Zare N. Does platelet-rich plasma enhance healing in the idiopathic bone cavity? A single-blind randomized clinical trial. *Int J Oral Maxillofac Surg.* 2015;44(9):1175-80. <http://dx.doi.org/10.1016/j.ijom.2015.05.011>. PMID:26074365.